

Table 1. Definitions of 1st Trimester Ultrasound Findings

IUP	Fundal gestational sac (GS) > 5mm surrounded by thick, concentric, echogenic ring, containing yolk sac (YS) or fetal pole (FP)
Abnormal IUP	GS > 10mm without a YS, GS > 16mm without a FP or FP > 5mm without fetal cardiac activity
Ectopic Pregnancy	GS surrounded by thick, concentric, echogenic ring containing YS or FP outside the fundus of uterus
NDIUP	All others

Suspected Ectopic Pregnancy?
 i.e. all females of child bearing age with abdominal pain, vaginal bleeding, lightheadedness, syncope, dyspareunia, nausea, shoulder pain or clinical concern

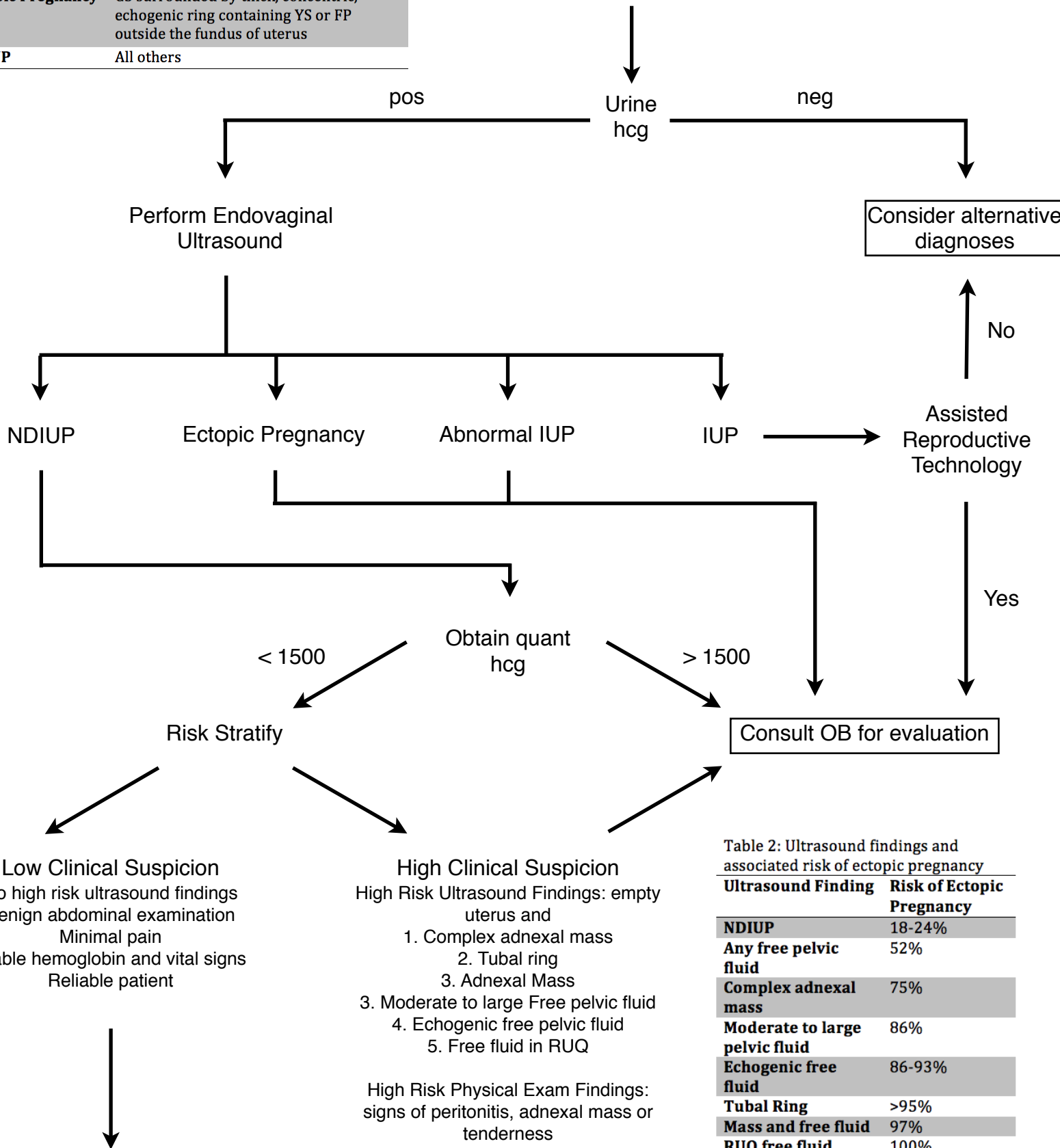


Table 2: Ultrasound findings and associated risk of ectopic pregnancy

Ultrasound Finding	Risk of Ectopic Pregnancy
NDIUP	18-24%
Any free pelvic fluid	52%
Complex adnexal mass	75%
Moderate to large pelvic fluid	86%
Echogenic free fluid	86-93%
Tubal Ring	>95%
Mass and free fluid	97%
RUQ free fluid	100%

Phone call to OB: Patient placed in Beta Book, 48 - 72h F/U for serial serum hcg levels and repeat ultrasound (Instruct patient to F/U in ED at 48h if she cannot be seen in clinic for any reason, e.g. holiday). D/C with strict ectopic precautions.